

## Combination therapy of pegaptanib sodium and photocoagulation in management of diabetic macular edema

Satabdi Sundaray, Mukesh K Singh, Taraprasad Das,  
L V Prasad Eye Institute, Bhubaneswar

Diabetic macular edema is one of the important causes of moderate visual loss in patients with diabetic retinopathy. Clinically there are four types of diabetic maculopathy- Clinically non-significant macular edema, Clinically significant macular edema, Ischemic maculopathy, and Cystoid macular edema. Loss of vision due to diabetic macular edema is about five times the visual loss due to complications of proliferative diabetic retinopathy. Traditionally laser photocoagulation has been considered the standard of care in diabetic macular edema. [1] The Early Treatment Diabetic Retinopathy Study (ETDRS) demonstrated that the laser treatment reduced the risk of moderate visual loss by approximately 50%, but vision improved in only less than one quarter patients.

Over last few decades one has understood the role of vascular endothelial growth factor (VEGF) in causation of diabetic retinopathy. VEGF is a potent cause of vascular leakage in the retina. It is mainly unregulated by hypoxia. There are five major isoforms of VEGF that arise from alternate slicing of a single gene; however, VEGF 165 is the predominant one and the most abundant isoform. The VEGF is implicated in several angiogenic and vascular retinopathy disorders. They include choroidal neovascular membrane (CNVM), diabetic retinopathy and vein occlusions. VEGF is present in aqueous and vitreous humor in eyes with proliferative retinal vascular disorders [2]. Therefore VEGF represents an ideal target of antiangiogenic therapy.

Currently three anti VEGF molecules are used in ophthalmology; two of them, Pegaptanib sodium (Macugen) and Ranibizumab (Lucentis) are approved by the USFDA and several other countries (Europe, Asia,

Australia) for use in CNVM secondary to AMD, and the third one, Bevacizumab, is used off-label for similar conditions. These molecules are also used in diabetic retinopathy (chiefly, the diabetic macular edema, DME), and in branch and central retinal vein occlusions. All molecules are injected intravitreally in 0.05 ml dose, and all of them need repeat injections at interval of 4-6 weeks. Intravitreal corticosteroid (triamcinolone, fluocinolone, and dexamethasone) are also used in treatment of diabetic macular edema. In many instances laser photocoagulation is combined with one of the intravitreal therapy. The suggested hypothesis is that the laser works better once the intravitreal therapy reduces the macular edema.

We report one such case where intravitreal pegaptanib sodium helped in reduction of macular edema and reversal of failing vision in a diabetic individual.

### Case report

LM, Sixty-four old male, known diabetic for 6 years, on treatment (insulin) reported with complaints of reduction of central vision left eye for seven months. He had earlier received laser photocoagulation elsewhere for diabetic macular edema left eye. The best corrected visual acuity was 20/20P, N6 right eye and 20/70, N8 left eye. Both eyes had early nuclear sclerosis. The applanation pressure was 14 mm Hg either eye. The fundus examination of the right eye was normal. The left eye showed a small circinate ring of exudates at macula, with micro aneurysms in the center of the exudates. Fluorescein angiography (FA) confirmed leaking micro aneurysms. The optical coherence tomography (OCT) confirmed presence of macular edema (central macular thickness 289  $\mu$ m)

Based on these evaluations a diagnosis of non-

proliferative diabetic retinopathy with persistent macular edema left eye status post laser photocoagulation was made. We administered additional laser photocoagulation left eye. But his left eye vision did not change in two months time. The macular edema persisted as per the FA and OCT (central macular thickness 345  $\mu\text{m}$ ) examination. We administered intravitreal triamcinolone acetonide (4 mg) two months after the laser photocoagulation. Two months following injection the visual acuity remained unchanged, though macular edema partially reduced (OCT central macular thickness 257  $\mu\text{m}$ ). This vision continued to reduce and by June 2007, six months following the first intravitreal triamcinolone, the visual acuity was 20/160. The fundus examination showed increase in size of the macular circinate ring of exudation and the central macular thickness on OCT was 406  $\mu\text{m}$ .

We advised a series of intravitreal Pegaptanib

Table 1. Clinical summary.

Date	Fundus	VA	CCT	Inference	Mx
Oct 2006	Circinate	20/70	289 $\mu\text{m}$		PHC Oct 2006
Dec 2006	CSME		345 $\mu\text{m}$	worse	IVTA Dec 2006
Jan 2007	CSME		389 $\mu\text{m}$	status quo	
Feb 2007	CSME		355 $\mu\text{m}$	status quo	
Mar 2007	CSME		257 $\mu\text{m}$	reduced edema	
May 2007	Circinate	20/160	406 $\mu\text{m}$	worse	IVTP Jun 2007
July 2007	CSME		494 $\mu\text{m}$	status quo	IVTP Jul 2007
Oct 2007	no circinate		157 $\mu\text{m}$	improved	
Nov 2008	dry macula		150 $\mu\text{m}$	status quo	Cataract Sx Jan 2009
Feb 2009	dry macula	20/50		dry macula.	

IVTA- Intravitreal Triamcinolone; IVTP- Intravitreal Pegaptanib; PHC- Photocoagulation

## Discussion

New pharmacological interventions at the molecular level show great promise in treating visually disabling conditions such as diabetic macular edema. Pegaptanib sodium is an aptamer (a synthetic oligonucleotide that binds to a target molecule) that selectively binds to the pathologic isoform of VEGF, VEGF 165. The aptamer is pegylated (bound to polyethylene glycol) to delay its metabolism in vivo. Pegaptanib (Macugen, Pfizer) was

sodium (Macugen). The first pegaptanib sodium was injected six months after the intravitreal triamcinolone and the second pegaptanib sodium injection was given a month after the first injection. Following the first injection there was no reduction of central macular thickness, but three months after the second injection there was complete reduction of the macular exudates; the central macular thickness on OCT measured 157  $\mu\text{m}$ . Since the cataract was progressing we did a cataract surgery six months after the second pegaptanib injection.

On last examination (28 months after the first laser by us; 26 months after the first intravitreal triamcinolone; 18 months after the second pegaptanib sodium injection; one year after the cataract surgery) the visual acuity remained stable at 20/50 in the left eye. The macula was dry.

The clinical summary is tabulated in Table 1; the clinical course is illustrated in Figure 1 and 2.

approved by the US FDA in 2004. It differs from other anti VEGF therapies in that it binds near the heparin-binding domain of VEGF, thus preventing VEGF 165 and larger isoforms from attaching to VEGF receptors instead of targeting all active VEGF-A isoforms.

A phase II prospective randomized, placebo controlled, double-masked, dose-ranging, multi center trial has been done using pegaptanib sodium.[3] The study compared three different doses of pegaptanib with sham

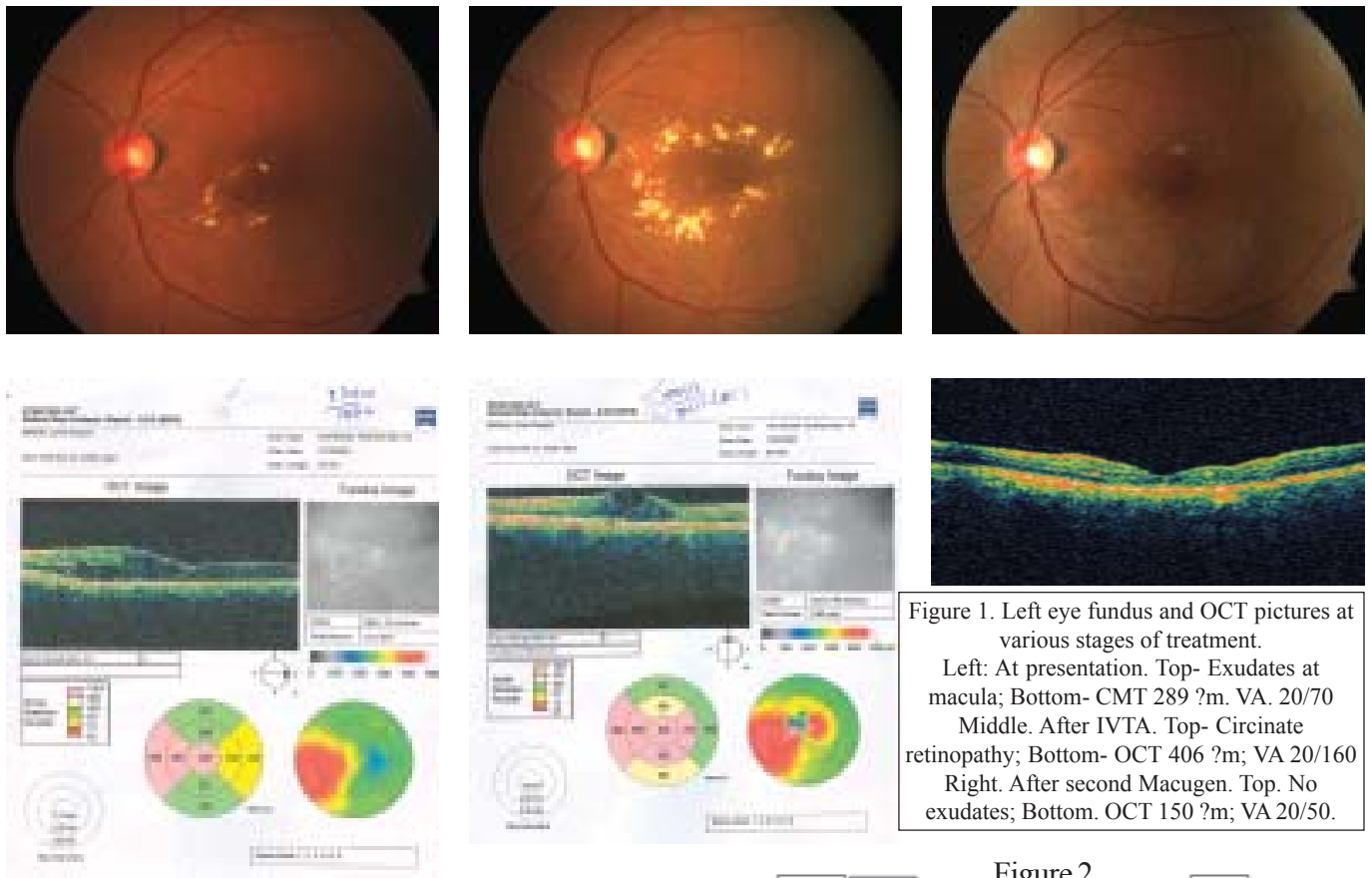


Figure 1. Left eye fundus and OCT pictures at various stages of treatment. Left: At presentation. Top- Exudates at macula; Bottom- CMT 289 μm. VA. 20/70 Middle. After IVTA. Top- Circinate retinopathy; Bottom- OCT 406 μm; VA 20/160 Right. After second Macugen. Top. No exudates; Bottom. OCT 150 μm; VA 20/50.

injection to evaluate its safety and efficacy in patients with diabetic macular edema over a 36-week period. A total of 172 patients who were otherwise eligible for thermal laser therapy for diabetic macular edema were enrolled. Patients received varying doses (0.3, 1 and 3 mg) of pegaptanib through an intravitreal injection or sham injection every 6 weeks for at least 12 weeks with additional injection and/or focal laser at the discretion of the investigators for another 18 weeks. Final assessment were conducted at 36 weeks.

The data were statistically significant for the 0.3 mg dose of pegaptanib sodium as compared to sham with respect to the following outcomes at 36 weeks: (1) a gain of >10 letters were experienced in 34% of pegaptanib patients (Vs 10% of sham patients), (2) mean central retinal thickness decreased by 68 μm in pegaptanib patients (Vs 4 μm increase in sham patients) and (3) photocoagulation was deemed necessary in 25% of pegatanib patients (Vs 48% of sham patients).

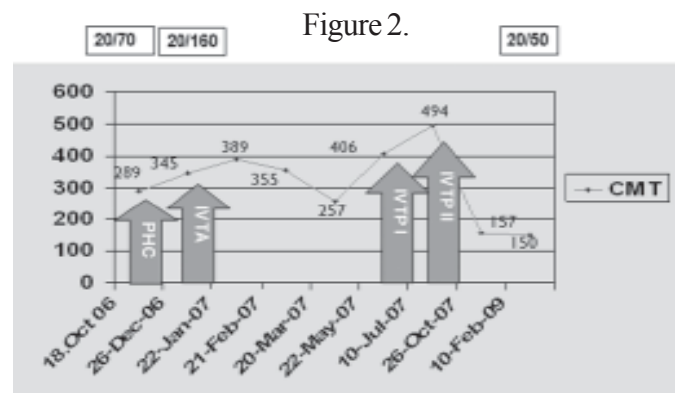


Figure 2. Measurement of the central macular thickness vis-à-vis intervention and visual acuity. CMT- Central macular thickness; IVTA- Intravitreal taimcinolone' IVTP- Intravitreal Pegatanib sodium; PHC- Photocoagulation.

Pharmacological therapy alone or in combination with laser therapy hold a great promise in management of diabetic macular edema.

(Presented in the Clinical meeting on April 12, 2009 at Cuttack)

□□□